

# Off-Label Use of Recombinant Human Bone Morphogenetic Protein-2 (rhBMP-2) for Reconstruction of Mandibular Bone Defects in Humans

Todd G. Carter, DMD,\* Pardeep S. Brar, DMD,†  
Andrew Tolas, DDS,‡ and O. Ross Beirne, DMD, PhD§

**Purpose:** The off-label use of recombinant human bone morphogenetic protein-2 (rhBMP-2) for the treatment of mandibular bone defects was evaluated in 5 patients. The rhBMP-2 was used as an alternative to autogenous bone grafting.

**Patients and Methods:** A total of 5 patients had mandibular defects reconstructed with rhBMP-2, 1.5 mg/mL, soaked collagen sponges alone or in combination with bone marrow cells and allogenic cancellous bone chips. Four of the patients had mandibular continuity defects and the fifth patient had 2 large bone cavities following removal of dentigerous cysts. Radiographs and clinical examinations were used to evaluate healing. The longest patient follow-up was 22 months after reconstruction.

**Results:** Radiographic and clinical assessments revealed bone regeneration and restoration of the mandibular defects in 3 of the 5 patients. The rhBMP-2 failed in 2 patients with continuity defects. Both patients with failed rhBMP-2 grafts were successfully repaired using autogenous harvested from the iliac crest.

**Conclusion:** Mandibular bone defects can be successfully reconstructed using rhBMP-2 soaked sponges with and without including bone marrow cells and allogenic bone. Further studies are needed to determine the ideal combination of components that will predictably and reliably regenerate bone in different types of bone defects.

© 2008 American Association of Oral and Maxillofacial Surgeons  
*J Oral Maxillofac Surg* 66:1417-1425, 2008

Reconstruction of large osseous mandibular defects due to pathology or trauma remains a challenge. Autogenous corticocancellous bone grafts, bone graft substitutes, microvascular tissue transfer, and distraction osteogenesis are among the numerous tech-

niques advocated to address the problem. The diversity of techniques is an indication of the difficulty of mandibular reconstruction. Despite the many advantages of autogenous grafts, disadvantages including donor site morbidity, limited availability of donor tissues, and limitations on graft shape and contour remain.<sup>1-6</sup>

Clinical applications of the inductive capacity of bone morphogenetic proteins (BMP) are increasingly showing the potential of this technology. Successful functional regeneration of critical size defects in the canine model was first reported in 1991.<sup>7</sup> The efficacy of recombinant human bone morphogenetic protein-2 (rhBMP-2) in 3 subhuman primate models was shown in resection defects in both young and old monkeys, as well as in ostectomy-created simulated bilateral maxillary cleft defects.<sup>8</sup> Seto et al<sup>9</sup> showed successful regeneration of segmental mandibular defects in a primate model using rhBMP-2 in a polyglycolic lactic acid carrier along with varied amounts of autogenous bone marrow.

The first reported human application of BMP in the mandible was reported by Moghaden et al in 2001.<sup>10</sup>

---

\*Private Practice, Wailuku, HI; and Formerly, Chief Resident, University of Washington, Department of Oral and Maxillofacial Surgery, Seattle, WA.

†Chief Resident, University of Washington, Department of Oral and Maxillofacial Surgery, Seattle, WA.

‡Private Practice, Kent, WA; and Clinical Associate Professor, University of Washington, Department of Oral and Maxillofacial Surgery, Seattle, WA.

§Professor and Chair, University of Washington, Department of Oral and Maxillofacial Surgery, Seattle, WA.

Address correspondence and reprint requests to Dr Beirne: University of Washington, Department of Oral and Maxillofacial Surgery, Box 357134, Seattle, WA 98195-7134; e-mail: slsb@u.washington.edu

© 2008 American Association of Oral and Maxillofacial Surgeons

0278-2391/08/6607-0015\$34.00/0

doi:10.1016/j.joms.2008.01.058

They reconstructed a 6-cm mandibular resection defect after removal of an ameloblastoma. The defect was reconstructed with a poloxamer-based gel containing 200 mg of native human BMP prepared from allogenic cortical bone and allogenic bone pieces. Bone formation was observed at 3 months and increased over 9 months of follow-up. A biopsy carried out at 9 months showed viable bone with numerous osteocytes.

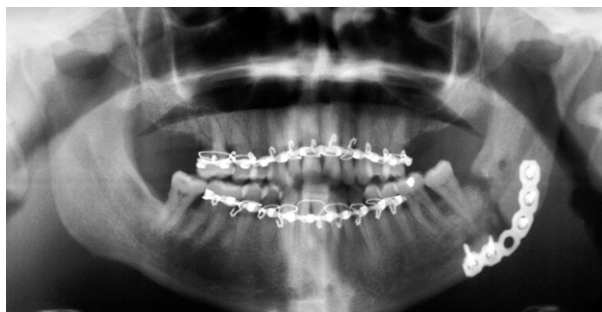A group of investigators used a heterotopic composite graft in minipigs. They combined recombinant human osteogenic protein 1 (rhOP-1) with xenogenic bone mineral in a titanium scaffold. These constructs were inserted into a latissimus muscle pouch to develop a heterotopic composite graft.<sup>11,12</sup> They applied this technique to a human patient in 2004.<sup>13</sup>

The purpose of this study is to present our experience with an off-label use of a commercially available rhBMP-2 (Infuse Medtronic-Sofamor Danek USA, Memphis, TN) for the reconstruction of mandibular bone defects. We present 5 cases of orthotopic mandibular reconstruction that show the possible use of rhBMP-2 for bone tissue engineering in patients with significant bony defects.

## Report of Cases

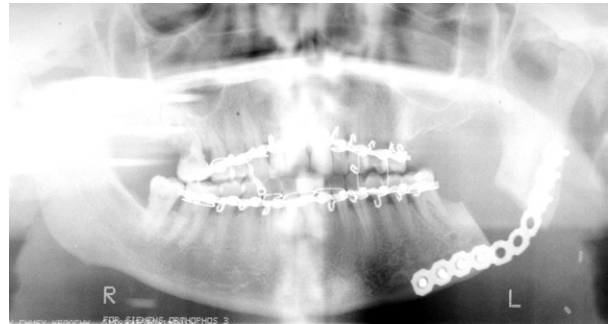
### CASE 1

A 42-year-old female presented to the emergency department at Harborview Medical Center (HMC) after an assault by a male acquaintance. Clinical and radiographic evaluation showed an open and displaced left mandibular angle fracture involving the erupted left mandibular third molar. The nearly avulsed third molar was removed immediately due to aspiration risk. The patient was treated initially with an intraoral open reduction and internal fixation (ORIF) using a 2.0-mm plate at the superior border and maxillomandibular fixation (MMF). She did not return until 6 weeks after repair of her fracture. She



**FIGURE 1.** Case 1. Panoramic radiograph shows a fibrous union at the fractured left angle of the mandible.

*Carter et al. rhBMP-2 in Tissue-Engineered Bone Grafts. J Oral Maxillofac Surg 2008.*



**FIGURE 2.** Case 1. Postoperative panoramic radiograph obtained after reconstruction of the mandibular defect using rhBMP-2.

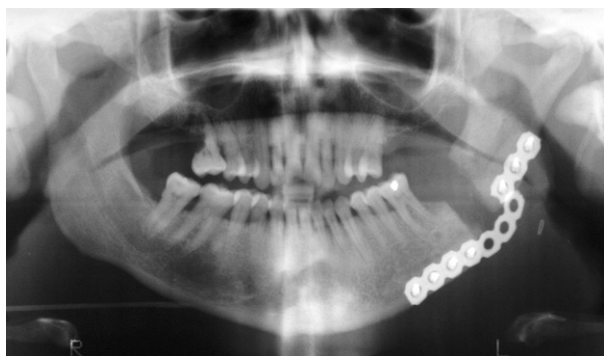
*Carter et al. rhBMP-2 in Tissue-Engineered Bone Grafts. J Oral Maxillofac Surg 2008.*

had removed the MMF and reported eating hard foods. She refused intervention and did not return until 5 months after the fracture repair.

When she returned, she had an infection with non-union of the fracture. The hardware was removed, the fracture was debrided, and a reconstruction plate was placed through an extraoral submandibular approach. She did not return for routine evaluations, and eventually her lower left second molar had to be removed. Because of continued discomfort and paresthesia, the reconstruction plate was removed and a fibrous union with proximal segment migration at the fracture was evident (Fig 1). The infection resolved and she agreed to reconstruction of the defect with rhBMP-2 to avoid possible morbidity associated with harvesting a bone graft from the iliac crest.

She was placed into MMF; the fibrous union and involved bone was excised through an extraoral submandibular approach; and a 2.4-mm locking reconstruction plate was applied. The defect was reconstructed with a total of 8.4 mg of rhBMP-2 (Infuse Medtronic-Sofamor Danek USA) reconstituted as 1.5 mg/mL solution and absorbed onto absorbable collagen sponges (ACS) following the manufacturer's recommendations. The rhBMP-2 collagen sponges were used to fill the bony defect and were enclosed within the periosteal envelope (Fig 2). The excised bone was cultured and grew 1+ coagulase negative *Staphylococcus* and 1+ *Propionibacterium*. Her postoperative course was remarkable for significantly more soft tissue swelling than is usually present after traditional reconstruction with autogenous bone. The patient's white cell count was not elevated and an aspiration and culture of a small quantity of fluid that was collected was negative for microorganisms.

The patient did not return until 8 months after the reconstruction. She presented complaining of right facial swelling and pain from a retained nonrestorable right maxillary first molar. She reported that 1 month before presenting for evaluation she heard a loud



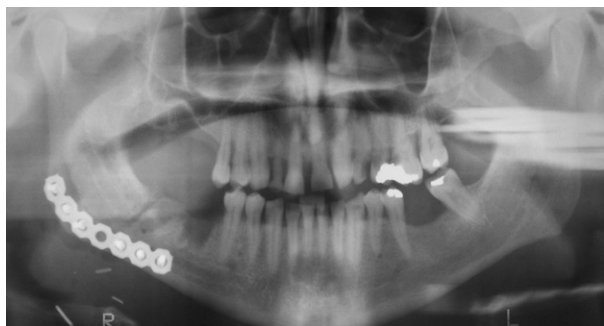
**FIGURE 3.** Case 1. Panoramic radiograph showing the fractured reconstruction plate and failure of rhBMP-2 reconstruction.

*Carter et al. rhBMP-2 in Tissue-Engineered Bone Grafts. J Oral Maxillofac Surg 2008.*

crack on the left while chewing. Panoramic radiograph showed fracture of the hardware and absence of bone regeneration in the left mandibular defect (Fig 3). An autogenous corticocancellous iliac crest bone graft was used to reconstruct her mandibular defect successfully.

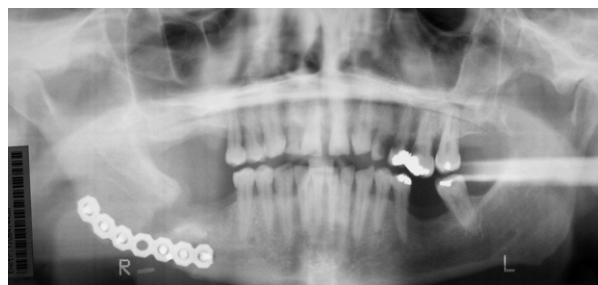#### CASE 2

A 43-year-old male presented to the HMC emergency room with a complaint of facial pain after an assault. Clinical and radiographic evaluation showed an open right mandibular angle fracture involving the mandibular right second molar. He was treated initially with ORIF of his mandible using a superior border 2.0-mm plate and MMF. The mandibular right second molar and periodontally involved opposing maxillary second and third molars were extracted. He returned to the clinic 10 days postoperatively with no MMF and broken hardware. The failed fixation plate was removed and a 2.4-mm locking reconstruction plate, which was placed through an extraoral submandibular approach, was used to stabilize the fracture (Fig 4). He returned 2 weeks later with an infec-



**FIGURE 4.** Case 2. Radiograph showing ORIF right angle fracture of the mandible with a 2.4-mm locking reconstruction plate.

*Carter et al. rhBMP-2 in Tissue-Engineered Bone Grafts. J Oral Maxillofac Surg 2008.*



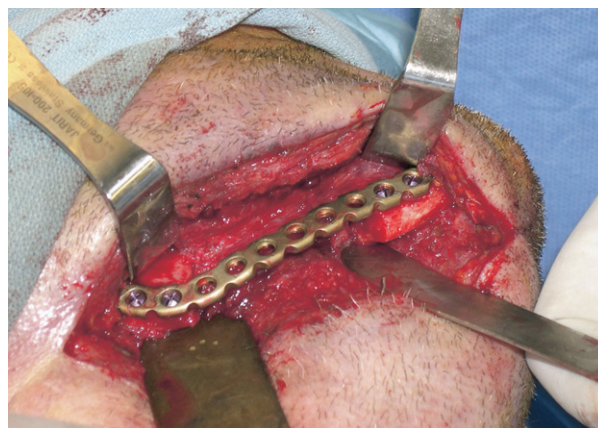
**FIGURE 5.** Case 2. Panoramic radiograph of the mandible with osteomyelitis at the right fracture.

*Carter et al. rhBMP-2 in Tissue-Engineered Bone Grafts. J Oral Maxillofac Surg 2008.*

tion that required incision and drainage (I&D). The patient left the hospital against medical advice immediately after the treatment. He periodically returned to the emergency department and affiliated clinics seeking antibiotics and pain medications for a progressing infection of the right mandible (Fig 5). Three months after the I&D he returned and agreed to surgical intervention to resolve the infection. He had segmental resection of necrotic bone and excision of a cutaneous sinus tract (Figs 6, 7).

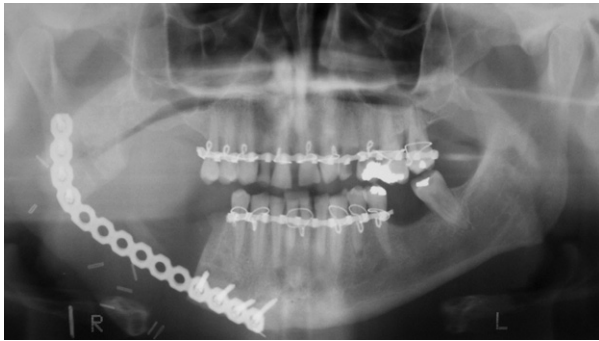
After 1 month of uneventful healing, reconstruction of the large continuity defect was planned. The patient was concerned about autogenous bone graft donor site morbidity and agreed to reconstruction with rhBMP-2. Because, in case 1, rhBMP-2 absorbed on a collagen sponge alone failed to regenerate bone, autogenous bone marrow and allogenic bone were combined with the rhBMP-2 impregnated collagen sponges to increase the osteogenic potential of the graft.

Under general anesthesia the patient's left iliac crest was cannulated with an intraosseous infusion



**FIGURE 6.** Case 2. Photograph showing the segmental resection of the right mandible stabilized with a 2.4-mm reconstruction plate.

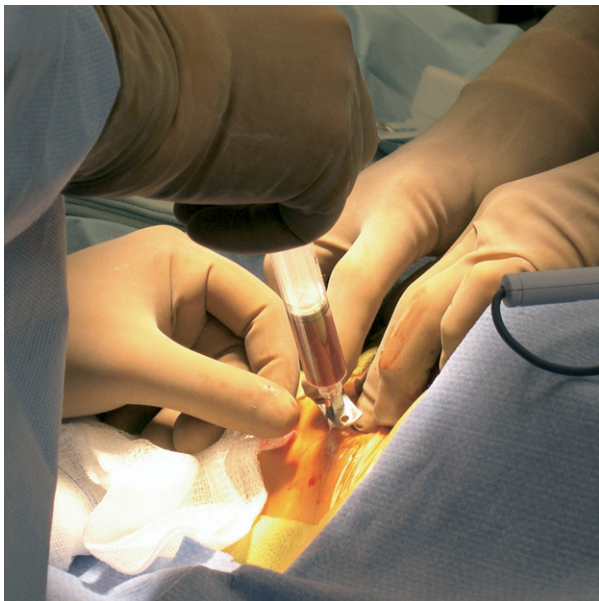
*Carter et al. rhBMP-2 in Tissue-Engineered Bone Grafts. J Oral Maxillofac Surg 2008.*



**FIGURE 7.** Case 2. Radiograph of the bone defect after segmental resection of infected bone.

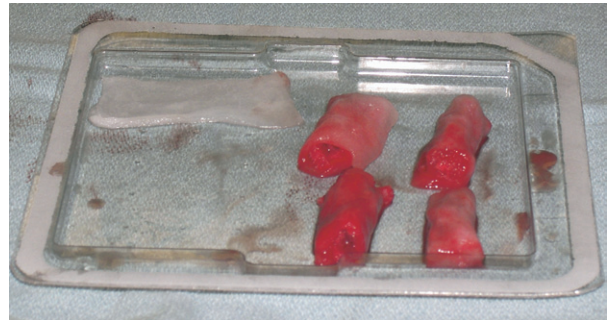
*Carter et al. rhBMP-2 in Tissue-Engineered Bone Grafts. J Oral Maxillofac Surg 2008.*

catheter (Dieckmann infusion needle) and 10 cc of marrow was aspirated (Fig 8). Allogenic cancellous bone chips (Northwest Tissue Center, Seattle, WA) were allowed to soak in the marrow aspirate while the recipient bed was prepared (Fig 9). The mandibular site was reopened via a submandibular approach and a recipient bed was created with careful attention to avoid intraoral exposure. The adjacent bony margins were freshened with a curette. The allogenic cancellous chips with the bone marrow cells were rolled into the rhBMP-2 impregnated collagen sponges. A total of 12 mg rhBMP-2 (Infuse Medtronic-Sofamor Danek USA) was reconstituted at 1.5 mg/mL and absorbed onto the collagen sponges following the manufacturer's recommendations. A rhBMP-2 satu-



**FIGURE 8.** Case 2. Photograph of syringe used to harvest 10 mL of bone marrow from the anterior hip.

*Carter et al. rhBMP-2 in Tissue-Engineered Bone Grafts. J Oral Maxillofac Surg 2008.*

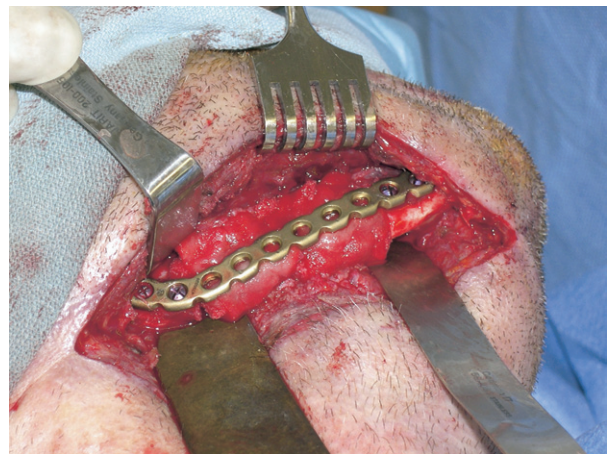


**FIGURE 9.** Case 2. Photograph of absorbable collagen sponges impregnated with rhBMP-2 wrapped around allogenic bone chips combined with autogenous bone marrow aspirate.

*Carter et al. rhBMP-2 in Tissue-Engineered Bone Grafts. J Oral Maxillofac Surg 2008.*

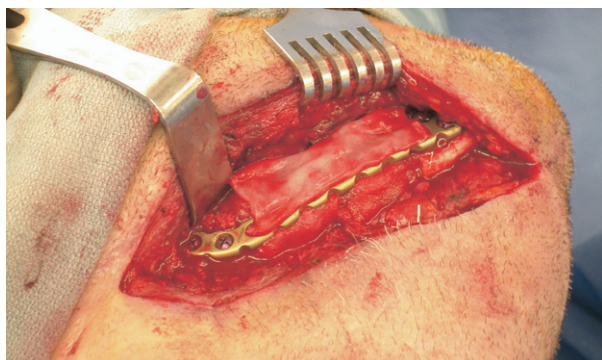
rated collagen sponge was placed on the medial of the defect and 4 rolls of the combination graft (rhBMP-2, bone marrow cells, allogenic cancellous bone) were placed into the defect. An additional rhBMP-2 saturated sponge was placed over the rolls on the lateral aspect of the defect (Figs 10, 11).

The patient did well postoperatively and was discharged the following morning. Like the first patient, this patient had significantly more swelling than is usually observed with an autogenous free bone graft. A panoramic radiograph at 2 months postoperatively shows induction of bone growth within the defect. Eight months after surgery the patient was still experiencing persistent pain at the reconstruction site. Because there was no infection and the continuity of the mandible was restored, the reconstruction plate was removed. The defect was bridged with regenerated bone (Figs 12, 13). The pain decreased and the



**FIGURE 10.** Case 2. Photograph of rhBMP-2 soaked collagen sponges filled with cancellous bone chips and bone marrow cells filling the bone defect.

*Carter et al. rhBMP-2 in Tissue-Engineered Bone Grafts. J Oral Maxillofac Surg 2008.*



**FIGURE 11.** Case 2. Photograph of rhBMP-2 soaked collagen sponge placed over the rolled rhBMP-2 soaked collagen sponges containing bone chips and bone marrow cells.

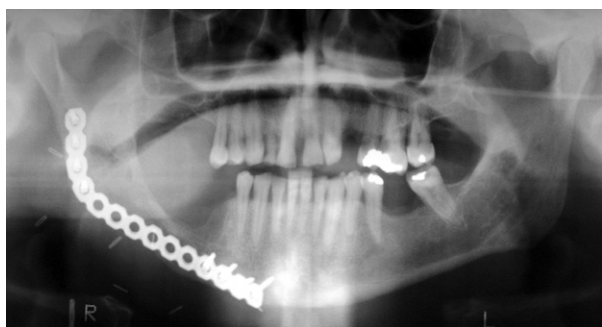*Carter et al. rhBMP-2 in Tissue-Engineered Bone Grafts. J Oral Maxillofac Surg 2008.*

reconstruction remained complete 22 months after placing the rhBMP-2 tissue engineered graft (Fig 14).

CASE 3

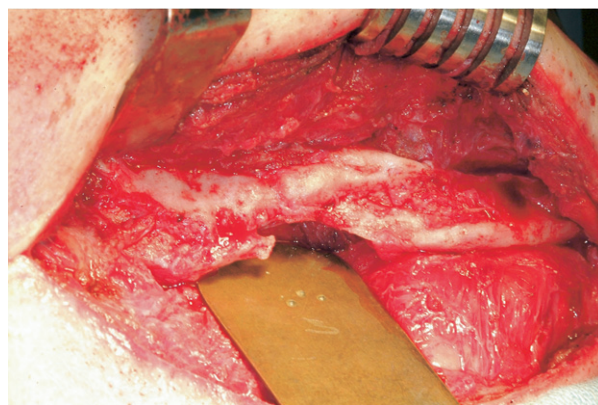
A 42-year-old female was brought to HMC after being struck by an automobile. The patient sustained multiple facial lacerations and a comminuted mandible fracture. During the postoperative period after repair of the injuries, the patient developed a non-union of her comminuted mandible fracture (Fig 15). After discussing the risks and benefits of various techniques for reconstruction, the patient decided to proceed with mandibular reconstruction using rhBMP-2 in combination with autogenous bone marrow cells and allogenic cancellous bone.

A total of 10 mL of bone marrow cells was aspirated from the patient's right anterior iliac crest using a Dieckmann intraosseous infusion needle. Allogenic cancellous bone chips (15 mL) (Northwest Tissue Center) were allowed to soak in the bone marrow aspirate while the recipient site was prepared. The rhBMP-2 impregnated sponges combined with autog-



**FIGURE 12.** Case 2. Panoramic radiograph 8 months after reconstruction with rhBMP-2 soaked collagen sponges combined with autogenous bone marrow aspirate and allogenic bone chips.

*Carter et al. rhBMP-2 in Tissue-Engineered Bone Grafts. J Oral Maxillofac Surg 2008.*



**FIGURE 13.** Case 2. Photograph of bone healing 10 months after reconstruction.

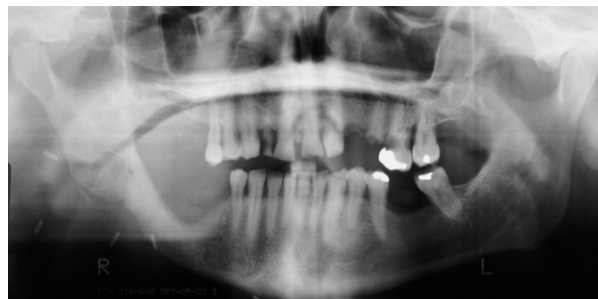*Carter et al. rhBMP-2 in Tissue-Engineered Bone Grafts. J Oral Maxillofac Surg 2008.*

enous bone marrow cells and allogenic cancellous bone were used to reconstruct the defect as described for case 2.

The patient, like the previous 2 patients, developed significantly more facial swelling than is usually seen with autogenous bone grafts. She developed mild cellulitis at her incision site, which responded well to oral antibiotics. There was good bone fill in the defect at 18 months (Fig 16).

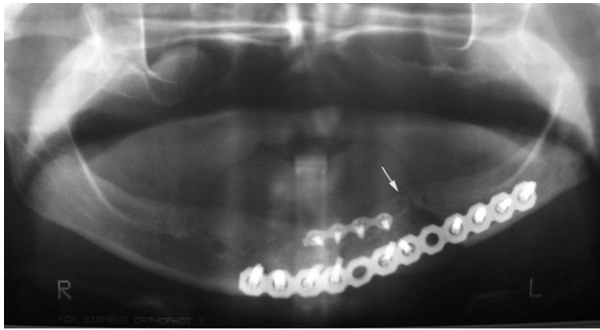
CASE 4

A 41-year-old female presented to HMC with a complaint of right facial swelling that was localized to the mandible. The mandibular right second premolar had been extracted at another facility. The patient underwent incision and drainage in the clinic and was admitted for intravenous antibiotics. A computed tomography scan showed a persistent fluid collection along with the finding consistent with osteomyelitis of the right mandible. The osteomyelitis extended from an area distal to the mandibular right first bicuspid to the angle of the right mandible.



**FIGURE 14.** Case 2. Panoramic radiograph 22 months after reconstruction.

*Carter et al. rhBMP-2 in Tissue-Engineered Bone Grafts. J Oral Maxillofac Surg 2008.*

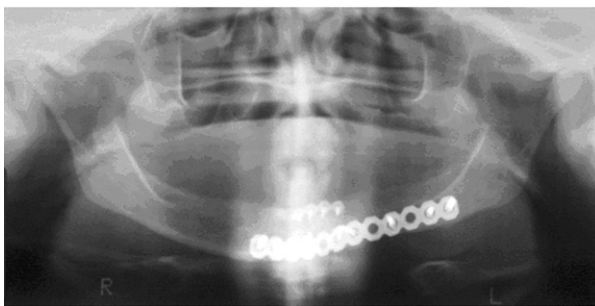


**FIGURE 15.** Case 3. Panoramic radiograph with arrow at the bony defect in the left mandible 3 months after repair of a comminuted mandible fracture.

Carter et al. *rhBMP-2 in Tissue-Engineered Bone Grafts*. *J Oral Maxillofac Surg* 2008.

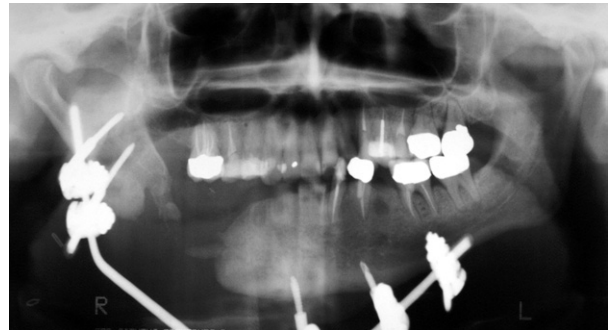The patient had multiple washouts and debridements of her mandible that subsequently required partial mandibulectomy of the right mandible after she developed a pathologic fracture. The patient was treated with multiple courses of intravenous antibiotics in the hospital as well as with home intravenous antibiotic therapy. The bacterial cultures grew *Streptococcus milleri* at initial presentation and later *enterococcus*.

After resection of the mandible, the patient required several I&Ds and subsequent plate removal with placement of an external fixation device. She received hyperbaric oxygen therapy (Fig 17) in addition to the intravenous antibiotic therapy. After 8 months, the patient's infection resolved completely and she underwent reconstruction of her mandible with rhBMP-2. The rhBMP-2 impregnated collagen sponges combined with autogenous bone marrow cells and allogenic cancellous bone were used to reconstruct the defect as described for cases 2 and 3. The defect was stabilized using the external fixation device and MMF. Like in the previous cases, the pa-



**FIGURE 16.** Case 3. Panoramic radiograph showing bone healing 12 months after reconstruction of the bone defect with rhBMP-2 combined with autogenous bone marrow aspirate and allogenic bone chips.

Carter et al. *rhBMP-2 in Tissue-Engineered Bone Grafts*. *J Oral Maxillofac Surg* 2008.



**FIGURE 17.** Case 4. Panoramic radiograph of the defect created by osteomyelitis at the right mandible. An external fixation device is stabilizing the mandible.

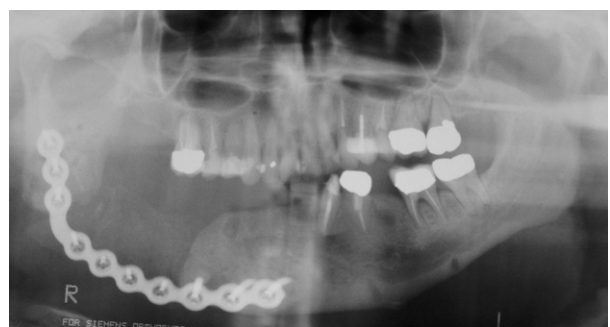
Carter et al. *rhBMP-2 in Tissue-Engineered Bone Grafts*. *J Oral Maxillofac Surg* 2008.

tient developed more soft tissue swelling during the immediate postoperative period than is usually observed with autogenous bone grafts.

Five months postoperatively, the patient had not developed a bony union. Her external fixation device was removed and she underwent an iliac crest bone graft reconstruction with placement of a 2.4-mm reconstruction plate to stabilize her continuity defect (Fig 18). The patient has continued to have a complicated postoperative course requiring the removal of the reconstruction plate and multiple I&Ds. The bone graft has healed with repair of the continuity defect.

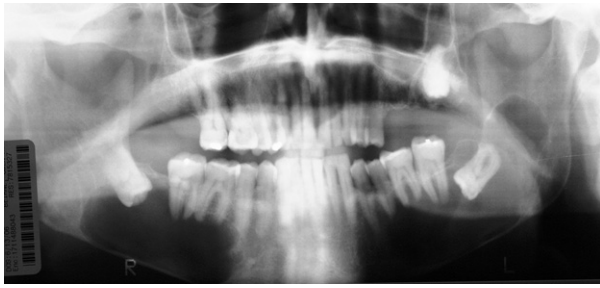#### CASE 5

An 81-year-old male was referred to HMC with a recent history of left facial swelling. A panoramic radiograph showed 2 radiolucent lesions in the mandible. A lesion on the left was associated with the crown of the impacted mandibular left third molar and one on the right was associated with the crown of the impacted right third molar (Fig 19). The patient underwent an incision and drainage of the swelling



**FIGURE 18.** Case 4. Panoramic radiograph showing the bone defect reconstructed with an iliac crest bone graft after failure of rhBMP, bone marrow aspirate, and allogenic cancellous bone graft.

Carter et al. *rhBMP-2 in Tissue-Engineered Bone Grafts*. *J Oral Maxillofac Surg* 2008.



**FIGURE 19.** Case 5. Panoramic radiograph showing 2 well-defined bilateral cystic lesions associated with the mandibular left and right third molars.

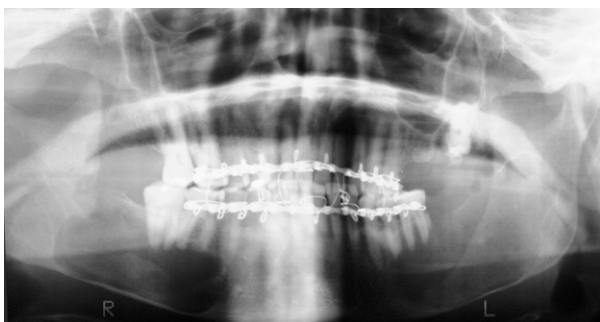*Carter et al. rhBMP-2 in Tissue-Engineered Bone Grafts. J Oral Maxillofac Surg 2008.*

on the left and was placed on oral antibiotics by his dentist. He was referred to Oral and Maxillofacial Surgery and when he presented, he had no signs of an acute infection.

A computed tomography scan showed a 4-cm lesion on the right and a 4.5-cm lesion on the left. Both lesions exhibited minimal bucco-lingual expansion. There was evidence of perforation at the lingual cortex on the left side. The inferior border of the mandible on the right and left was intact, and there was no evidence of pathologic fracture. It appeared that the mandibular left second molar had a periodontal pocket on the distal surface, which may have caused the infection in the lesion on the left.

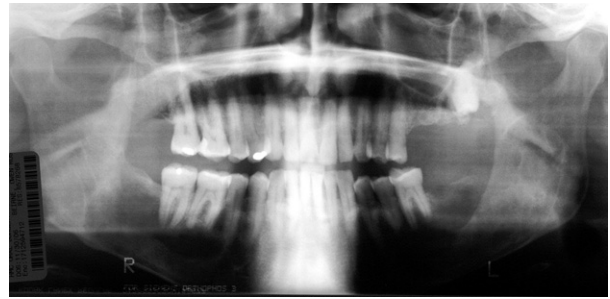Because of the history and radiographic findings, dentigerous cysts and odontogenic keratocysts were high on the differential diagnosis. The patient agreed to have the lesions enucleated and was informed that MMF may be required after surgery to prevent pathologic fracture.

The surgical procedure included application of maxillary and mandibular arch bars, extraction of the mandibular right and left third molars and the left mandibular second molar, enucleation, and curettage



**FIGURE 20.** Case 5. Panoramic radiograph 2 weeks after enucleation, curettage of the cysts, and placement of rhBMP-2 soaked collagen sponges.

*Carter et al. rhBMP-2 in Tissue-Engineered Bone Grafts. J Oral Maxillofac Surg 2008.*



**FIGURE 21.** Case 5. Panoramic radiograph taken 6 months postoperatively after enucleation, curettage, and application of rhBMP. There is increased bone density at both of the defects.

*Carter et al. rhBMP-2 in Tissue-Engineered Bone Grafts. J Oral Maxillofac Surg 2008.*

of both mandibular lesions. The clinical findings were consistent with dentigerous cysts. Two large hollow defects remained with a small perforation on the lingual cortex of the left mandible. The remaining lingual bony walls were intact along with a thick cortical inferior border. A total of 12 mg rhBMP-2 (Medtronic-Sofamor Danek USA) absorbed onto collagen sponges (1.5 mg/mL) was placed into the defects. Microfibrillar collagen (Avitene; CR Bard Inc, Murray Hills, NJ) was also placed into the bony cavities to aid in hemostasis and obliterate the dead space (Fig 20).

One week after surgery, the patient was doing well. Unlike the first 4 cases, the patient did not have unexpected soft tissue swelling. The final pathology reports confirmed that the lesions were dentigerous cysts. The patient continued to have an uneventful postoperative course and has good bone deposition in both bony cavities (Fig 21).

## Discussion

BMPs are mesenchymal cell differentiation factors and members of the transforming growth factor-beta (TGF- $\beta$ ) superfamily. The BMP subfamily is a group of low molecular weight proteins (19-30 kDa) with a pattern of 7 conserved cysteine residues conferring activity at the carboxy terminal end.<sup>10</sup> The first description of bone morphogenetic proteins is credited to Dr Marshall Urist. Dr Urist extracted BMPs from demineralized bone matrix and preserved their inductive capacity.<sup>14</sup> Recombinant human BMPs were produced successfully in 1988.<sup>15</sup>

The Food and Drug Administration approved rhBMP-2 (Infuse) for autograft replacement in spinal fusions in 2002. In 2004, rhBMP-2 was approved for adjuvant use in open tibia fractures and in March, 2007, rhBMP-2 was approved "as an alternative to autogenous bone graft for sinus augmentations, and for localized alveolar ridge defects associated with extraction sockets."<sup>16</sup> The use of rhBMP-2 in the 5

cases described in this study constituted an off-label use. The use of rhBMP-2 absorbed onto collagen sponges is contraindicated in patients with hypersensitivity to rhBMP-2 or bovine type I collagen, in areas of active infection, in areas of resected or extant tumor, in patients with active malignancy, and in patients who are pregnant or expecting pregnancy within 1 year.<sup>16</sup> In addition, the manufacturer's physician labeling recommends a precaution for using rhBMP-2 in patients less than 18 years of age because rhBMP-2 has not been studied in patients who are skeletally immature.<sup>16</sup> However, Chin et al<sup>17</sup> and Herford et al<sup>18</sup> have used rhBMP-2 off-label in patients from 6 to 18 years old without systemic complications.

The rhBMP-2 is costly. However, because there is no need to harvest an autogenous bone graft, operating room use and inpatient stay may be shortened, which could significantly decrease hospital costs and make the cost for reconstruction with rhBMP-2 comparable to an autogenous graft reconstruction. Comparative studies need to be done to determine if rhBMP-2 reconstruction is cost-effective relative to autogenous grafting.

The 5 cases described in this study have many similarities and differences. Cases 1, 2, and 4 represented patients who were poorly compliant and socio-economically disadvantaged. The third case represented a patient with a comminuted fracture with a residual continuity defect. The last case represented a patient with benign dentigerous cysts. All of the cases were without significant soft tissue deficiency. The reconstructions with rhBMP-2 were tolerated well, even though there was significant unexpected postoperative swelling at the surgical site. Clinicians using rhBMP for anterior cervical spine fusions observed significantly more swelling when rhBMP-2 was included in the graft compared with patients that were treated without rhBMP-2.<sup>19</sup> Like in the first case described in this report, 3 patients with cervical spine fusions that had more swelling than typically observed after the fusion were evaluated for hematoma or infection, and only diffuse soft tissue swelling was found. The cause of the atypical soft tissue swelling associated with rhBMP-2 is unknown.

Several factors contributed to graft failure in the 2 patients that did not regenerate bone with the rhBMP-2. Case 1 did not have signs of clinical infection at the time of reconstruction with rhBMP-2; however, bacteria were cultured from the resected bone. It is possible that this low level of bacteria may have had a negative effect on bone induction. The success of rhBMP-2 depends on the presence of appropriate stem cells in the local environment to differentiate into bone forming cells. Although the rhBMP-2 was placed in a periosteal envelope, the chronicity of the

infection in case 1 may have decreased the stem cell population's ability to respond to the rhBMP-2. It is also possible that soft tissue swelling compressed the collagen sponges at the graft site and eliminated the space needed for bone growth. Case 1 may have needed a mineralized osteoconductive scaffold to achieve bone fill of the defect.

When cancellous allograft bone was included in cases 2, 3, and 4, 2 patients had successful regeneration of bone in their continuity defects. The cancellous allograft may have acted as an osteoconductive scaffold or a space maintainer to allow bone ingrowth. Herford et al<sup>18</sup> successfully reconstructed a mandibular continuity defect in a 12-year-old using only the rhBMP-2 absorbed in the collagen and bone plates to provide "tenting" to maintain space for bone ingrowth.

In many reconstructions, rhBMP-2 absorbed to a collagen sponge is sufficient to induce bone formation; however, the diffusion of the water soluble rhBMP-2 from the collagen sponge may be too rapid to permit complete bone healing of a large continuity defect.<sup>20</sup> The therapeutic outcome of rhBMP-2 depends on its quantity, concentration, and time of application.<sup>21,22</sup> Therefore, it is important to use an appropriate carrier system for the delivery, retention, and release of BMPs at the implanted site.<sup>23</sup> In addition, it is important to maintain space for bone ingrowth.

The cause of graft failure in case 1 cannot be determined but was likely due to the combination of chronic infection, significant swelling, limited number of stem cells, lack of an osteoconductive scaffold, and inadequate maintenance of space for bone ingrowth. When autogenous bone marrow and allogenic cancellous bone were included in the graft for cases 2 and 3, there was bone regeneration in the defects. Space maintenance with an allogenic cancellous osteoconductive bone scaffold, as well as the introduction of mesenchymal stem cells from the bone marrow aspirate, may have produced the successful outcome in cases 2 and 3.

Case 4 failed even with the inclusion of autogenous bone marrow aspirate and allogenic cancellous bone with the rhBMP-2. This patient had an infection that was refractory to treatment. She required hyperbaric oxygen treatment in addition to long-term antibiotic treatment to resolve the osteomyelitis. Even the autogenous corticocancellous bone graft from the iliac crest has been slow to heal.

A conventional iliac crest graft was chosen for the secondary treatment in the 2 failed cases because the safety and effectiveness of repeat application of rhBMP-2 has not been established. There are transient increases in antibodies to BMP-2 in 5% to 10% of patients treated with rhBMP, which does not affect bone healing



on the first exposure, but the effects of second exposure to the same BMP have not been established.<sup>24</sup>

The bone defect in case 5 was significantly different from the other 4 cases. The residual mandibular defects were not continuity defects. The patient had 2 bony cavities, each with 3 walls, after removal of the 2 cysts. Bone regeneration was successful with rhBMP-2 absorbed on the collagen sponge alone without the addition of bone marrow aspirate and allogenic bone. The wall of the bone cavity maintained space for bone ingrowth, and there were probably adequate stem cells and osteoblasts at the surgical sites to regenerate bone.

Tissue engineered osteoinductive grafts may someday eliminate the need for harvesting corticocancellous grafts. A combination of osteoinductive proteins, stem cells, and osteoconductive scaffolds will likely be needed to achieve predictable reconstruction of many bony defects whereas other defects may only require rhBMP-2 absorbed on a matrix. The cases described in this study show that it is possible to reconstruct mandibular defects with osteoinductive proteins produced using recombinant DNA technology. However, more studies are needed to develop the ideal combination of factors that can predictably and reliably regenerate bone in different defects. Our results as well as others<sup>10,17-19</sup> show that rhBMP-2 will probably play a significant role in these tissue engineered bone grafts.

## References

- Ahlmann E, Patzakis M, Roidis N, et al: Comparison of anterior and posterior iliac crest bone grafts in terms of harvest-site morbidity and functional outcomes. *J Bone Joint Surg Am* 84A:716, 2002
- Heary RF, Schlenk RP, Sacchieri TA, et al: Persistent iliac crest donor site pain: Independent outcome assessment. *Neurosurgery* 50:510, 2002
- Kalk WWI, Raghoobar GM, Jansma J, et al: Morbidity from iliac crest bone harvesting. *J Oral Maxillofac Surg* 54:1424, 1996
- Beirne OR: Comparison of complications after bone removal from lateral and medial plates of the anterior ilium for mandibular augmentation. *Int J Oral Maxillofac Surg* 15:269, 1986
- Marx RE, Morales MJ: Morbidity from bone harvest in major jaw reconstruction: A randomized trial comparing the lateral anterior and posterior approaches to the ilium. *J Oral Maxillofac Surg* 46:196, 1988
- Tayapongsak P, Wimsatt JA, LaBanc JP, et al: Morbidity from anterior ilium bone harvest. A comparative study of lateral versus medial surgical approach. *Oral Surg Oral Med Oral Pathol* 78:296, 1994
- Toriumi DM, Kotler HS, Luxenberg DP, et al: Mandibular reconstruction with a recombinant bone inducing factor. *Arch Otolaryngol Head Neck Surg* 117:1101, 1991
- Boyne P: Application of bone morphogenetic proteins in the treatment of clinical oral and maxillofacial osseous defects. *J Bone Joint Surg Am* 83A:S146, 2001
- Seto I, Asabina I, Oda M, et al: Reconstruction of the primate mandible with a combination graft of recombinant human bone morphogenetic protein-2 and bone marrow. *J Oral Maxillofac Surg* 59:53, 2001
- Moghadam HG, Urist T, Sandor GK, et al: Successful mandibular reconstruction using a BMP bio-implant. *J Craniofac Surg* 12:119, 2001
- Terheyden H, Knak C, Jepsen S, et al: Mandibular reconstruction with a prefabricated vascularized bone graft using recombinant human osteogenic protein-1: An experimental study in miniature pigs. Part I: Prefabrication. *Int J Oral Maxillofac Surg* 30:373, 2001
- Terheyden H, Warnke P, Dunsche A, et al: Mandibular reconstruction with a prefabricated vascularized bone graft using recombinant human osteogenic protein-1: An experimental study in miniature pigs. Part II: Transplantation. *Int J Oral Maxillofac Surg* 30: 469, 2001
- Warnke PH, Springer IN, Wiltfang J, et al: Growth and transplantation of a custom vascularized bone graft in a man. *Lancet* 364:766, 2004
- Urist MR, Granstein R, Nogami H, et al: Transmembrane bone morphogenesis across multiple walled diffusion chambers. *Arch Surg* 122:612, 1977
- Wozney JM, Rosen V, Celeste AJ, et al: Novel regulators of bone formation: Molecular clones and activities. *Science* 242:1528, 1988
- 2.1 Physician labeling (3/8/2007). Infuse bone graft for certain oral maxillofacial and dental regenerative uses. Important medical information, Rx only. Available at: <http://www.fda.gov/cdrh/pdf5/p050053c.pdf>. Accessed December 18, 2007
- Chin M, Ng T, Tom W, et al: Repair of alveolar clefts with recombinant human bone morphogenetic protein (rhBMP-2) in patients with clefts. *J Craniofac Surg* 16:778, 2005
- Herford AS, Boyne PJ, Williams RP: Clinical applications of rhBMP-2 in maxillofacial surgery. *J Calif Dent Assoc* 35:335, 2007
- Smucker JD, Rhee JM, Singh K, et al: Increased swelling complications associated with off-label usage of rhBMP-2 in the anterior spine. *Spine* 31:2813, 2006
- Nakahara H, Takaoka K, Koezuka M, et al: Periosteal bone formation elicited by partially purified bone morphogenetic protein. *Clin Orthop* 239:299, 1989
- King GN, Cochran DL: Factors that modulate the effects of bone morphogenetic protein-induced periodontal regeneration: A critical review. *J Periodontol* 73:925, 2002
- Pang EK, Im SU, Kim CS, et al: Effects of recombinant human bone morphogenetic protein-4 dose on bone formation in rat calvarial defects. *J Periodontol* 75:1364, 2004
- Kim CS, Kim JI, Kim J, et al: Ectopic bone formation associated with recombinant human bone morphogenetic proteins-2 using absorbable collagen sponge and beta tricalcium phosphate carriers. *Biomaterial* 26:2501, 2005
- Boden SD: ABC's of BMPs. *Orthop Nurs* 24:49, 2005